

Radiological Study of Maxillary Sinus using CBCT: Relationship between Mucosal Thickening and Common Anatomic Variants in Chronic Rhinosinusitis

MARCO CAPELLI¹, PATRIZIA GATTI²

ABSTRACT

Introduction: Inflammatory diseases of the maxillary sinus favour the thickening of the sinus mucosa. Therefore, it might be possible to establish a radiological, pathological threshold of mucosal thickening. Furthermore, there is an association between common anatomic variants of the nose and maxillary mucosal thickening.

Aim: To define the pathological thickening of maxillary sinus mucosa and its association with the presence of common anatomic variants (concha bullosa, Haller's cell and accessory maxillary ostium).

Materials and Methods: From March 2014 to February 2016, Two hundred patients underwent Cone Beam Computed Tomography (CBCT) of the paranasal sinus. We conducted this retrospective study of total 70 patients, 34 patients i.e., a total of 68 meatus-maxillary units (study group - those affected by Chronic Rhinosinusitis (CRS) and another 36 patients i.e., a total of 72 meatus maxillary units (control group - without symptoms of CRS). We assessed the degree of thickening of

the sinus mucosa distinguishing between $\geq 2\text{mm}$ or $\leq 2\text{mm}$, than we analysed the behaviour of the thickness in the study group and in the control group. Chi-Square test was used to compare mucosal thickening between study and control group and the presence of some common anatomic variants or closure of maxillary ostium.

Results: In the study group we observed a clear association between maxillary mucosal thickening $\geq 2\text{mm}$ and CRS ($p < 0.01$). We however, observed no association between the presence of common anatomic variations and thickening of the maxillary mucosa and between the presence of common anatomic variations and the study group. Instead, using a binary logistic regression, we observed a significant association ($p < 0.01$) between closure of natural ostium of the maxillary sinus and mucosal thickening or between closure of natural ostium and study group.

Conclusion: We believe that a thickening of the maxillary mucosa $\geq 2\text{mm}$ and closure of natural maxillary ostium are statistically associated with CRS. The common anatomical variants do not seem to be associated with this condition.

Keywords: Concha bullosa, Haller cell, Inflammatory diseases, Maxillary accessory ostium, Sinus mucosa

INTRODUCTION

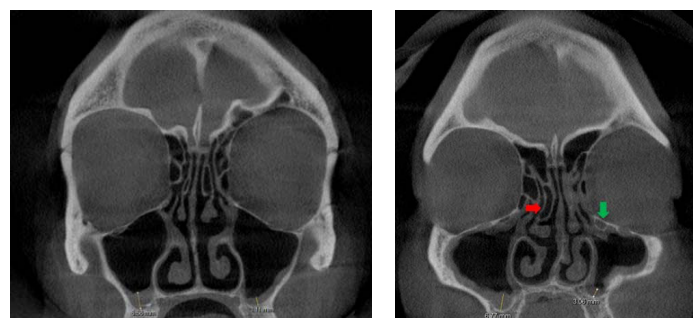
Several authors have studied the relationship between anatomic variants of the middle meatus and the incidence of Chronic Rhinosinusitis (CRS) [1]. Conclusions reported by a great part of literature are discordant. Indeed in contrast with many authors [2-6] who assert that CRS is favored by the presence of anatomic variants, other authors believe that CRS is not related to any anatomic variant [1]. In order to establish the presence of a relationship between CRS and anatomic variants, it is mandatory to establish when sinonasal mucosa is pathological. According to Som [7] sinonasal mucosa should not be visible and any thickening should be considered anomalous. However, the progressive evolution of radiological instrumentations has led to an ever greater image definition. Some authors [8-10] have therefore, defined more precisely a threshold of mucosal thickening above which it is correct to diagnose sinonasal pathology. Maillet et al., defined that a mucosal thickening $\geq 2\text{mm}$ is indicative of sinus inflammation [11]. In the indexed study we first established the level of mucosal thickening associated with maxillary sinus inflammation and then verified its effective relationship with common anatomical variants (concha bullosa, maxillary accessory ostium and Haller cell). Finally, we tested the relationship between thickening of the sinus mucosa and obstruction of the maxillary ostium.

MATERIALS AND METHODS

A retrospective study was conducted on 70 patients. All patients came to our Rhinological Center from March 2014 to February 2016

and underwent a Cone Beam Computed Tomography (CBCT) of the maxillary sinus by Galileos GAX9 (Sirona Dental System GmbH Bensheim, Germany). The images were analysed by Sidexis XG software (Sirona X-ray Imaging System Next Generation, Sirona Dental System GmbH, Bensheim, Germany) [Table/Fig-1,2].

All patients performed a 15 days long preparatory treatment before CBCT, using nasal washes with saline and no one was been previously treated with vasoconstrictors. Moreover, before the CBCT, a nasal endoscopy and a cytological analysis of the mucosa were performed for all the patients. These assessments allowed us to exclude patients with acute rhinosinusitis. We also excluded the patients who were previously treated with endoscopic nasal surgery, had allergic rhinitis, maxillary cysts, sinonasal polyposis, odontogenic sinusitis, fungal sinusitis, sinonasal mucocele, neoplastic diseases,



[Table/Fig-1]: Measurement of mucosal thickening of maxillary sinus [facial CBCT, coronal section]. **[Table/Fig-2]:** Mucosal thickening, Concha bullosa (red arrow) and Haller's cell (green arrow) [facial CBCT coronal section].

severe systemic metabolic disorders and cystic fibrosis. Thus, using axial and coronal scans, both osteo-meatal complex together with maxillary sinuses were analysed for a total of 140 meatus-maxillary units.

We divided the population into two groups: the study group, which included 34 patients (68 meatus-maxillary units) formed by patients presenting symptoms of CRS in accordance with the European Position Paper on Rhinosinusitis and Nasal Polyps 2012 criteria (EPOS), and the control group which included 36 patients (72 meatus-maxillary units) formed by patients who did not present symptoms of CRS. All patients gave their informed consent for the examination. We evaluated in each patient the degree of thickening of the mucosa of the maxillary sinus distinguishing between < or ≥ 2mm. We evaluated the relationship between thickening of the maxillary mucosa and the presence of some common anatomical variants (concha bullosa, accessory maxillary ostium and Haller cell) and the relationship between symptoms of CRS and the presence of those anatomic variants. Finally, we evaluated the association between the closure of maxillary ostium and maxillary mucosal thickening as well as the relationship between a close ostium and CRS.

Statistical analyses were done using dedicated software programs: MINITAB Inc. 17 and R Development Core Team (2015). A p-value less than 0.01 were considered statistically significant in Chi-square tests and in binary logistic regressions.

RESULTS

Of the 70, 36 were females and 34 males, aged between 14 and 80 years with a mean age of 46 years [Table/Fig-3].

Chi-square test was used to compare: the mucosal thickening between study and control group [Table/Fig-4]; the presence of anatomic variations (e.g., concha bullosa, Haller's cell, accessory

Age (years)	n	%
14 -35	18	25.71
35 -45	15	21.43
45 -60	19	27.15
60 -80	18	25.71
Mean-age (years)	45.69	
Standard deviation-age (years)	15.45	

[Table/Fig-3]: Sample structure by age.

Group	Mucosal Thickening		p-value
	< 2mm	≥ 2mm	
Study	4	64	< 0.01
Control	51	21	

[Table/Fig-4]: Chi-square test to compare mucosal thickening between study and control group.

Group	Concha bullosa		p-value
	Present	Absent	
Study	28	40	>0.01
Control	32	40	
Accessory Ostium			
Study	14	54	> 0.01
Haller's cell			
Study	31	37	> 0.01
Control	24	48	
Natural sinus ostium			
Study	31	37	<0.01
Control	69	3	

[Table/Fig-5]: Chi-square tests to compare anatomical variants and the natural sinus ostium between study group and control group.

Mucosal Thickening (mm)	Concha bullosa		p-value
	Present	Absent	
< 2	26	29	> 0.01
≥ 2	34	51	
Accessory Ostium			
< 2	18	37	> 0.01
≥ 2	20	65	
Haller's cell			
< 2	24	31	> 0.01
≥ 2	31	54	
Natural Sinus Ostium			
< 2	54	1	< 0.01
≥ 2	46	39	

[Table/Fig-6]: Chi-square tests to compare anatomical variations between mucosal thickening <2 and ≥2mm.

Mucosal Thickening	Coefficient	p-value
Concha bullosa		
Present	0.044	> 0.01
Absent	0.0	
Haller's Cell		
Present	-0.641	> 0.01
Absent	0.0	
Accessory Ostium		
Present	0.210	> 0.01
Absent	0.0	
Natural sinus ostium		
Open	0.0	< 0.01
Close	3.99	

[Table/Fig-7]: Binary logistic regression between mucosal thickening and the presence of common anatomic variants and natural sinus ostium. Final model
0: Mucosal Thickening< 2
1: Mucosal Thickening ≥ 2
Mucosal Thickening = - 0.16 + 3.82 . Natural Sinus Ostium (Close)

Group	Coefficient	p-value
Concha bullosa		
Present	-0.336	> 0.01
Absent	0.0	
Haller's Cell		
Present	-0.522	> 0.01
Absent	0.0	
Accessory Ostium		
Present		> 0.01
Absent	0.0	
Natural sinus ostium		
Open	0.0	<0.01
Close	-3.355	

[Table/Fig-8]: Binary logistic regression between the membership to a specific group and the presence of common anatomic variants and natural sinus ostium. Final model
0: Studygroup
1: Control group
Group = 0.8 - 3.312 . Natural Sinus Ostium (Close)

ostium and natural sinus ostium) between study and control group [Table/Fig-5] and between mucosal thickening < 2mm and ≥ 2mm [Table/Fig-6];

A binary logistic regression was used to prove the relationship between closed natural sinus ostium and the presence of a mucosal thickening ≥ 2mm [Table/Fig-7] and the membership of patients to the study group [Table/Fig-8].

In our study, we considered 140 sides (e.g., 68 from the study group and 72 from the control group). There was a statistically significant

Anatomic variation	Total		Male		Female	
	n	%	n	%	n	%
Concha bullosa	37	52.86	19	27.15	18	25.71
Right	8	11.43	1	1.43	7	10.00
Left	6	8.57	3	4.29	3	4.29
Bilateral	23	32.86	15	21.43	8	11.43
Haller's cell	32	45.72	18	25.71	14	20.01
Right	1	1.43	1	1.43	0	0.00
Left	8	11.43	5	7.14	3	4.29
Bilateral	23	32.86	12	17.14	11	15.72
Accessory Ostium	29	41.43	13	18.57	16	22.86
Right	9	12.86	3	4.29	6	8.57
Left	11	15.71	5	7.14	6	8.57
Bilateral	9	12.86	5	7.14	4	5.72

[Table/Fig-9]: Sample structure by anatomic variants.

relationship between mucosal thickening ≥ 2 mm and membership of patients to the study group [Table/Fig-4].

Then, we analysed anatomic variations in order to determine their effects on the severity of mucosal thickening and if the patients truly belonged to the specific group.

The most common anatomic variant was concha bullosa, present in 52.9% of our population, then the Haller cell (in 45.7%) and finally the accessory maxillary ostium (41.4%). They were also calculated for the incidence rates of anatomic variants in male and female population and compared with each other. We did not find statistically significant differences between genders [Table/Fig-9].

DISCUSSION

There are still many doubts about the radiological definition of chronic maxillary rhinosinusitis. According to Som, sinus mucosa in normal conditions should not be evident and its thickening would be considered pathological [7]. Conversely other authors defined a significant thickening of the sinus mucosa to be normal [12-15]. Rak et al., stated that a mucosal thickening > 3 mm can be detected in an asymptomatic patient [12] while Phothikhun et al., concluded that a 5mm thickness in many cases is not accompanied by clinical manifestations [13]. We believe that a correct knowledge of the maxillary inflammatory disease and its radiological presentation has a clinical importance and is of fundamental importance in the planning of certain surgical procedures such as sinus augmentation. As for the mucosal thickening, we used the criteria of Maillet et al., and Lu et al., in which the thickening of the mucosa beyond 2 mm was considered pathological [11,16]. Our data show that a maxillary mucosal thickening ≥ 2 mm is statistically associated to CRS according to EPOS2012. We also observed a statistically significant association between healthy patients and maxillary mucosa thickening < 2 mm [Table/Fig-4]. Therefore, we had considered a thickening of maxillary mucosa ≥ 2 mm as pathological.

After establishing a pathological mucosal thickness, we evaluated the relationship between the presence of common anatomical variants and maxillary disease. Among the known anatomical variants we have studied the concha bullosa, the maxillary accessory ostium and Haller cell, because of their easily visible radiological features. The concha bullosa was described for the first time in 1862 by Zuckerkandl who called it a pneumatization of the middle turbinate. Since then many authors have debated its correct definition. Some authors define the concha bullosa as any pneumatization of middle turbinate while others consider it a pneumatization corresponding to 50% of the vertical diameter of the turbinate [1]. In our study, we considered concha bullosa as any pneumatization of middle turbinate. The incidence of concha bullosa varies widely in literature (14-53%) [1]. In our study population, we observed an incidence of 52.9% of concha bullosa with a similar distribution between males

and females. Also the incidence of accessory maxillary ostium is widely varied (0-43%) [17] as the incidence of the Haller cell (2-45%) [1,2,5]. We observed an accessory maxillary ostium in 41.4% of the population and an Haller cell in 45.7%. We did not observe a significant prevalence according to gender [Table/Fig-9]. Results of our study and few other authors [1,18], show that anatomic variants analysed are not significantly associated with symptoms of CRS [Table/Fig-8] and furthermore, they are not significantly associated with an abnormal thickening of the maxillary mucosa [Table/Fig-7].

Finally, we observed a significant relationship between the closure of the natural maxillary ostium, pathological thickening of the mucosa and symptoms of CRS. These data, according to Carmeli et al., suggest an evident influence from natural ostium towards the status of maxillary sinus [19]. We believe that, the ostium-infundibulum unit should therefore, be subject to new and more extensive research in order to understand more clearly the pathogenetic mechanisms of chronic maxillary rhinosinusitis. According to other authors we also emphasize the usefulness of CBCT for the radiological study of diseases of the paranasal sinuses [20].

CONCLUSION

We conclude that in patients with CRS a mucosa maxillary thickening ≥ 2 mm, is not associated with the presence of concha bullosa, accessory maxillary ostium and Haller cell. Finally, in patients with CRS and pathological thickening of the maxillary mucosa we observed an association with the closure of the natural maxillary ostium.

ACKNOWLEDGEMENTS

Dr. Matilde Grecchi, for her contribution to the statistical analysis and data presentation.

REFERENCES

- [1] Stallman JS, Lobo JN, Som PM. The incidence of concha bullosa and its relationship to nasal septal deviation and paranasal sinus disease. *AJNR Am J Neuroradiol.* 2004;25(9):1613-18.
- [2] Shin JM, Baek BJ, Byun JY, Jun YJ, Lee JY. Analysis of sinonasal anatomical variations associated with maxillary sinus fungal balls. *Auris Nasus Larynx.* 2016 Jan 22. pii: S0385-8146(15)30013-4.
- [3] Fadda GL, Rosso S, Aversa S, Petrelli A, Ondolo C, Succo G. Multiparametric statistical correlations between paranasal sinus anatomic variations and chronic rhinosinusitis. *Acta Otorhinolaryngol Ital.* 2012;32(4):244-51.
- [4] Nouraei SA, Elisay AR, Dimarco A, Abdi R, Majidi H, Madani SA, et al. Variations in paranasal sinus anatomy: implications for the pathophysiology of chronic rhinosinusitis and safety of endoscopic sinus surgery. *J Otolaryngol Head Neck Surg.* 2009;38(1):32-37.
- [5] Bolger WE, Butzin CA, Parsons DS. Paranasal sinus bony anatomic variations and mucosal abnormalities: CT analysis for endoscopic sinus surgery. *Laryngoscope.* 1991;101(1 Pt 1):56-64.
- [6] Meloni F, Mini R, Rovasio S, Stomeo F, Teatini GP. Anatomic variations of surgical importance in ethmoid labyrinth and sphenoid sinus. A study of radiological anatomy. *Surg Radiol Anat.* 1992;14(1):65-70.
- [7] Som PM. CT of paranasal sinus. *Neuro Radiol.* 1985;27:189-201.
- [8] Sheikh M, Pozve NJ, Khorrami L. Using cone beam computed tomography to detect the relationship between the periodontal bone loss and mucosal thickening of the maxillary sinus. *Dent Res J (Isfahan).* 2014;11(4):495-501.
- [9] Guerra-Pereira I, Vaz P, Faria-Almeida R, Braga AC, Felino A. CT maxillary sinus evaluation--A retrospective cohort study. *Med Oral Patol Oral Cir Bucal.* 2015;20(4):e419-26.
- [10] Abrahams JJ, Glassberg RM. Dental disease: A frequently unrecognized cause of maxillary sinus abnormalities? *AJR Am J Roentgenol.* 1996;166(5):1219-23.
- [11] Maillet M, Bowles WR, McClanahan SL, John MT, Ahmad M. Cone-beam computed tomography evaluation of maxillary sinusitis. *J Endod.* 2011;37(6):753-57.
- [12] Rak KM, Newell JD, Yakes WF, Damiano MA, Luethke JM. Paranasal sinuses on MR images of the brain: significance of mucosal thickening. *AJR Am J Roentgenol.* 1991;156(2):381-84.
- [13] Phothikhun S, Suphanantachart S, Chuenchompoonut V, Nisapakulorn K. Cone-beam computed tomographic evidence of the association between periodontal bone loss and mucosal thickening of the maxillary sinus. *J Periodontol.* 2012;83(5):557-64.
- [14] Soikkonen K, Ainamo A. Radiographic maxillary sinus findings in the elderly. *Oral Surg Oral Med Oral Pathol Oral Radiol Endod.* 1995;80(4):487-91.
- [15] Vallo J, Suominen-Taipale L, Huuonen S, Soikkonen K, Norblad A. Prevalence of mucosal abnormalities of the maxillary sinus and their relationship to dental

- disease in panoramic radiography: results from the Health 2000 Health Examination Survey. *Oral Surg Oral Med Oral Pathol Oral Radiol Endod.* 2010;109(3):e80-87.
- [16] Lu Y, Liu Z, Zhang L, Zhou X, Zheng Q, Duan X, et al. Associations between maxillary sinus mucosal thickening and apical periodontitis using cone-beam computed tomography scanning: a retrospective study. *J Endod.* 2012;38(8):1069-74.
- [17] Prasanna LC, Mamatha H. The location of maxillary sinus ostium and its clinical application. *Indian J Otolaryngol Head Neck Surg.* 2010;62(4):335-37.
- [18] Kim HJ, Jung Cho M, Lee JW, Tae Kim Y, Kahng H, Sung Kim H, et al. The relationship between anatomic variations of paranasal sinuses and chronic sinusitis in children. *Acta Otolaryngol.* 2006;126(10):1067-72.
- [19] Carmeli G, Artzi Z, Kozlovsky A, Segev Y, Landsberg R. Antral computerized tomography pre-operative evaluation: relationship between mucosal thickening and maxillary sinus function. *Clin Oral Implants Res.* 2011;22(1):78-82.
- [20] Cakli H, Cingi C, Ay Y, Oghan F, Ozer T, Kaya E. Use of cone beam computed tomography in otolaryngologic treatments. *Eur Arch Otorhinolaryngol.* 2012;269(3):711-20.

PARTICULARS OF CONTRIBUTORS:

1. Doctor, ENT Casa di Cura "Lecco", Lecco, Italy.
2. Doctor, ENT Casa di Cura "Lecco", Lecco, Italy.

NAME, ADDRESS, E-MAIL ID OF THE CORRESPONDING AUTHOR:

Dr. Marco Capelli,
 Doctor, ENT Casa Di Cura Città Di Lecco Lecco, Lecco, Italy.
 E-mail: info@otorinocremona.it

FINANCIAL OR OTHER COMPETING INTERESTS: None.

Date of Submission: **Jun 28, 2016**
 Date of Peer Review: **Aug 05, 2016**
 Date of Acceptance: **Sep 17, 2016**
 Date of Publishing: **Nov 01, 2016**